

Pilot Study: Intratesticular Injection Induces Sterility in Male Cats

Alper BARAN¹, O. Banu OZDAS¹, Ahmet GULCUBUK², A. Izem HAMZAOGLU¹, Menekse TONGUC¹
¹Istanbul University, College of Veterinary Medicine, Department of Reproduction and Artificial Insemination, Avcilar-Istanbul/TURKEY
²Istanbul University, College of Veterinary Medicine, Department of Pathology, Avcilar-Istanbul/TURKEY

Introduction

The presence of large populations of stray cats leads to adverse impacts on cat welfare and public health in Istanbul-Turkey. The aim of this study was to evaluate the clinical safety and efficacy of a single intratesticular injection of calcium chloride in causing sterility of male adult cats and to document the incidence of sterility produced by such treatment as evidenced by semen analysis.

Material and Methods

Four male cats of mixed breed age from one to three years old and weighing between 3.5 and 4.0 kg were selected in this study. Three male cats (C1, C2 and C3) were injected with calcium chloride (10, 20, 40 mg concentrations) 0.2 ml/per testis. The control male cat (C4) received a single bilateral intratesticular injection of 0.2 ml sterile saline (0.2 ml/per testis). All animals were examined for testicular size, and, testosterone level and spermogram were performed before chemical injection, on Day 0 and then every 20 days for 2 months. General attitude, appetite, ability to walk, scrotal pain, rectal temperature, and scrotal evaluation beyond swelling were assessed on days 1-7 post-injection. Semen was evaluated for volume, sperm motility (%) and sperm morphology. Castration was then performed using a routine surgical procedure at 60 days after intratesticular calcium chloride injection. Testes from each animal were used for histomorphological studies.

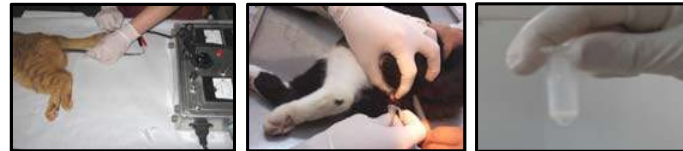

Fig. 1-2-3. Semen collection with electro-ejaculator (P-T Electronics) before injection of CaCl₂

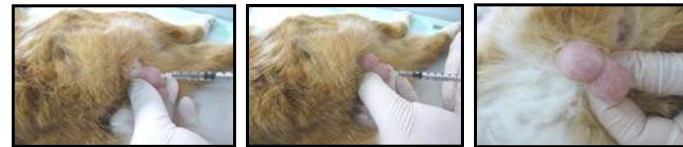

Fig. 4-5-6. Injection of calcium chlorid solution into the right and left testis of the male cat

Results

No biting or licking was recorded at six hour post-injection. No scrotal pain occurred on the 1st day post-injection. Post-injection, the scrotum of all male cats was swollen or the testis was sore or there was minor irritation. There was no significant change in rectal temperature on the 7 days post-injection. There was no significant change in blood parameters at 20, 40 and 60 days post-injection. Abnormal attitude and abnormal appetite were not seen and no difficulty with walking after injection was recorded for any of the male cats. Semen collection and analysis was the primary indicator of treatment efficacy, and semen collection was attempted in all male cats at the 20, 40 and 60 days post-injection. Semen could not be collected successfully by electro-ejaculation from C3 (high-dose) male cat after injection. High dose of calcium chloride injected into the testes could have caused serious damage in seminiferous tubules and caused this situation. The other three semen samples (C1, C2 and control C4) had live and motile sperm in the ejaculate; two of the animals (C1 and C2, low-dose and medium dose) were found to be oligospermic (less than 20×10^6 /mL), and the control male cat was found to have sperm greater than 20×10^6 per mL.

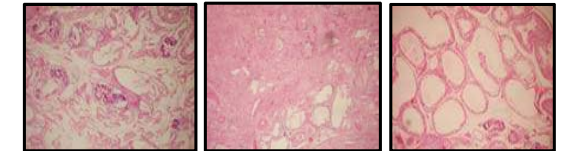


Fig. 7-8-9: Calcification, fibrosis and tubulus degeneration of C3 cat testis

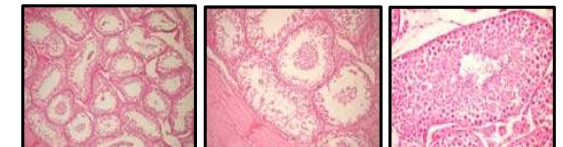


Fig. 10-11-12: Vacuolization and spermatogenesis of C4, C2 and C1 cat testis

Testicular histology showed the degenerative changes associated with the graded doses of calcium chloride. The efficacy of calcium chloride (C3, 40 mg) in inducing sterilization was supported by the degeneration and calcification of the seminiferous tubules and interstitial cells, along with the significant fibrosis (Fig.7-8-9).

Conclusion

Results indicate that intratesticular injection of calcium chloride is a well-tolerated and extremely effective method for non-surgical chemical sterilization of male cats.

References

- FAHIM M.S., WANG M., SUTCU M.F., FAHIM Z., YOUNGQUIST R.S. : Sterilization of dogs with intra-epididymal injection of zinc arginine. *Contraception*, 1993, 47, 107-122
- IMMIGART H.M., THRELFALL W.R. : Evaluation of intratesticular injection of glycerol for nonsurgical sterilization of dogs. *Am. J. Vet. Res.*, 2000, 61, 544-549.
- WEINBAUER G.F., GALHOTRA M.M., NIESCHLAG E. : Focal testicular destruction following intratesticular injection of glycerol in rats. *Int. J. Androl.*, 1985, 8, 365-375.